

Immediate loading of a Neoss ProActive® Tapered implant to correct upper right lateral incisor agenesis.

Dr. Roberto Romano, Italy

Patient: 22 year-old woman.

Clinical situation: Agenesis of the upper right lateral incisor with a tissue deficiency on the buccal aspect.

Treatment plan: Placement and immediate loading of a Neoss ProActive® Tapered implant restored with a screw-retained zirconia crown.

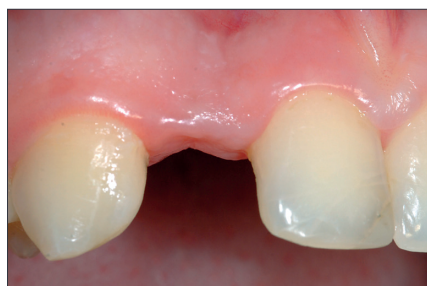

Figure 1

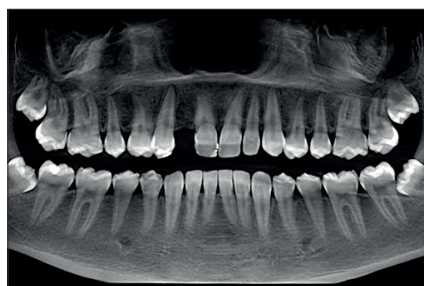

Figure 2

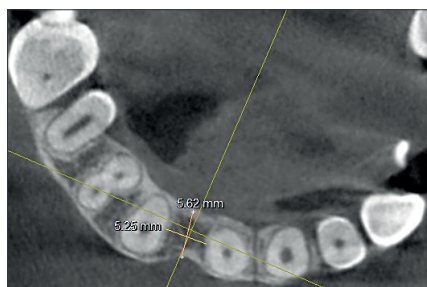

Figure 3

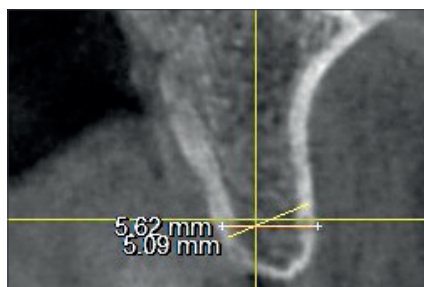


Figure 4

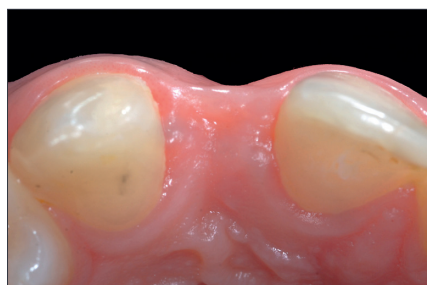

Figure 5

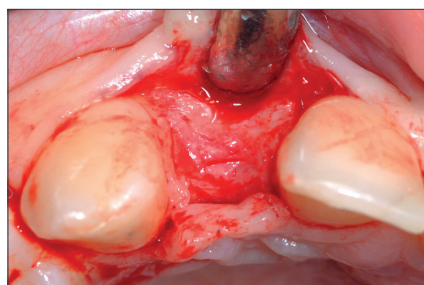


Figure 6

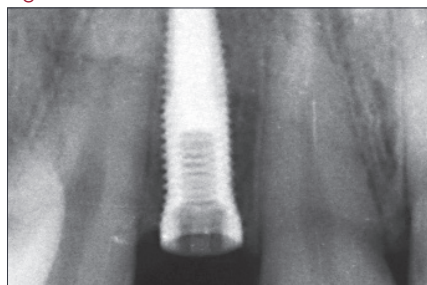


Figure 7

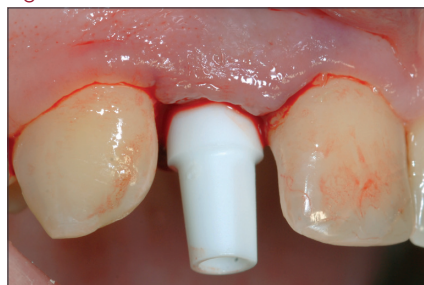

Figure 8

The patient needed an implant to replace the upper right lateral incisor missing due to agenesis (Figure 1 and 2).

The CBCT scan showed a residual bone width of 5.6 mm in the palatal-buccal and 5.2 mm in the mesio-distal direction (Figure 3 and 4).

Although the amount of bone was sufficient for implant placement, the soft tissue on the buccal aspect showed a concave profile (Figure 5).

In order to reduce the treatment time, and thus the esthetic discomfort for the patient, the decision was taken to apply an immediate loading protocol.

A full-thickness flap was raised on the buccal aspect in order to expose the surgical site (Figure 6).

A Neoss ProActive® Tapered Implant 3.5 x 13 mm was placed with a final insertion torque of 50 Ncm and 65 ISQ (Figure 7).

A screw-retained provisional crown previously manufactured by the lab was adapted to a Neoss Esthetic Tissue Former – Narrow Incisor (Figure 8 and 9).

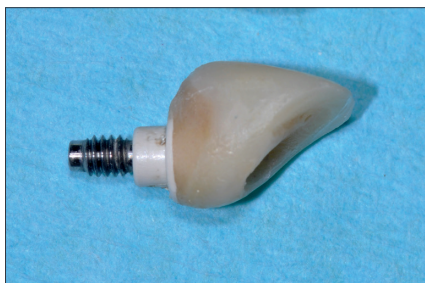

Figure 9

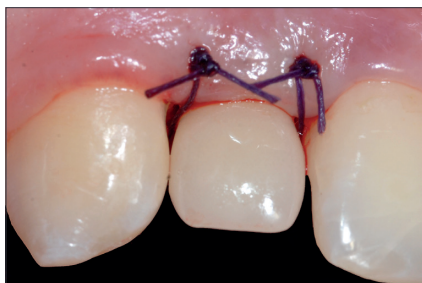

Figure 10

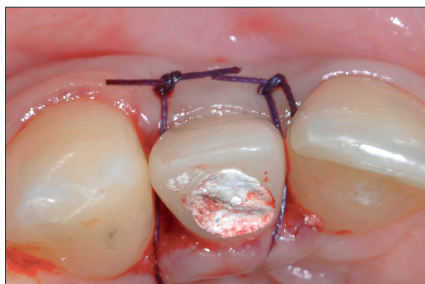

Figure 11

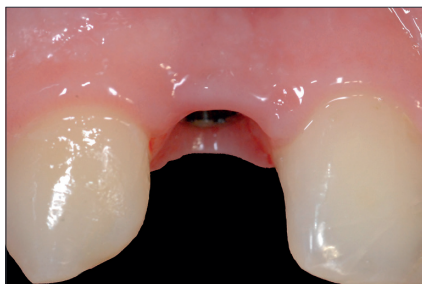


Figure 12

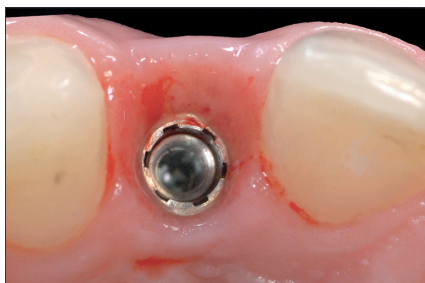

Figure 13

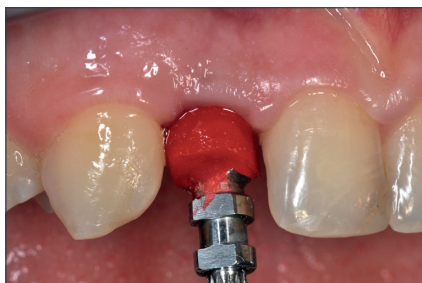

Figure 14

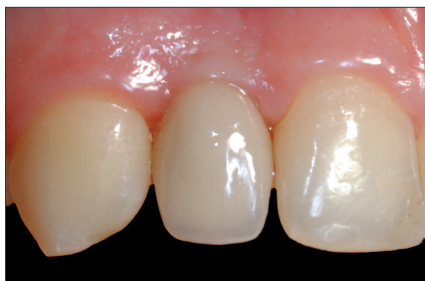

Figure 15

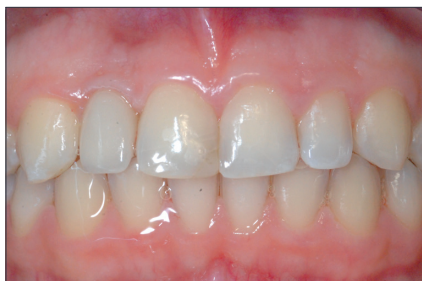

Figure 16

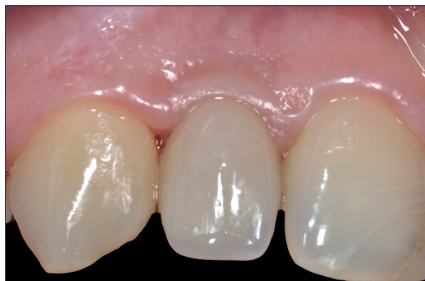

Figure 17

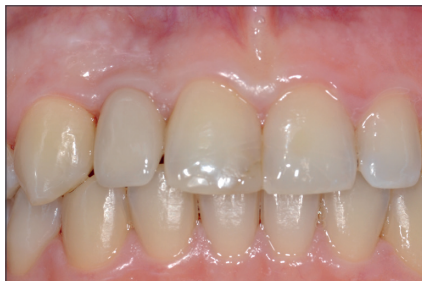

Figure 18

The crestal incision was slightly palatally displaced in order to correct the lack of soft tissue on the buccal aspect when the flap was sutured (Figure 10 and 11).

The concave aspect of the soft tissue on the buccal aspect appears corrected after 3 months of healing (Figure 12 and 13).

Final impression was taken with a customized impression coping aimed to replicate the trans-mucosal path shaped by the provisional crown (Figure 14).

The final restoration was a zirconia abutment with ceramic layered on the buccal aspect (Figure 15 and 16).

After 3.6 years from the definitive restoration delivery, soft and hard tissue levels were stable and the esthetic aspect was satisfactory (Figure 17 and 18).